

# Tamoxifen Alone or in Combination with Estradiol-17 $\beta$ Inhibits the Growth and Malignant Transformation of Hepatic Hyperplastic Nodules\*†

SHAINDEL Y. MISHKIN,‡ EMMANUEL FARBER,§ RUKIN HO,§|| SHREE MULAY‡ and SEYMOUR MISHKIN¶\*\*

¶Department of Medicine, Royal Victoria Hospital and McGill University Clinic, Montreal H3A 1A1, Canada,

‡Department of Clinical Endocrinology, Royal Victoria Hospital, Montreal, Canada, and §Department of Pathology, University of Toronto, Canada

**Abstract**—Hepatic hyperplastic nodules (HHNs) induced by the 'resistant hepatocyte method' of Solt et al. were studied as an experimental prototype of oral contraceptive-related tumors. Cytoplasmic estrogen receptors were present in all HHNs harvested and their concentration was always less than that in normal liver. No specific cytoplasmic progesterin receptors could be measured in the above tumor or liver specimens. The long-term administration of estradiol-17 $\beta$  (4.8–24.0  $\mu$ g/day) resulted in the death of all but one of 20 animals prior to termination at 10 months. Tamoxifen (0.25–2.5 mg biweekly), which did not lead to excess mortality, decreased HHN grade (proportion of liver slice occupied by HHN) and inhibited malignant transformation. Combination therapy with single-dose estradiol-17 $\beta$  (4.8  $\mu$ g/day) and various doses of tamoxifen (0.25–2.5 mg biweekly) in most cases reduced mortality, HHN grade and malignant transformation. Cytoplasmic progesterin receptors were absent and estrogen receptors were either undetectable or present in low concentrations in hepatic tumors harvested at the time of termination. Our results indicated that HHNs are hormone-dependent and that malignant transformation can be inhibited by tamoxifen alone or in combination with estradiol-17 $\beta$ .

## INTRODUCTION

WITH a view to developing medical therapies for oral contraceptive-related hepatic tumors we have studied two experimental models of HHNs which resemble these tumors histologically [1]: AAF-induced HHNs (4 cycles of 0.02% AAF in the diet) [2] and the 'resistant hepatocyte model' of Solt et

al. [3]. Thus far we have documented the presence of cytoplasmic estrogen receptors in both HHN models [4] and have observed that the proliferation and malignant transformation (by histological criteria) of AAF-induced HHNs is inhibited by long-term treatment with single empirically chosen doses of estradiol-17 $\beta$  and/or tamoxifen [5]. This communication describes the results of analogous experiments carried out in male Fischer rats harboring 'resistant hepatocyte model' HHNs [3].†† In this study various doses of estradiol-17 $\beta$  and tamoxifen were administered to 4-month-old rats in contrast to the previous experiment, in which single dosages were used. In addition to the measurement of estrogen receptors, assays for cytoplasmic progesterone receptors

Accepted 25 October 1984.

\*This work was supported by grants from the Medical Research Council of Canada, the Cedars Cancer Fund of the Royal Victoria Hospital.

†This work is dedicated to the memory of Mr Moe Yalovsky.

||Present address: Department of Pathology, Guanxi Medical College, Guanxi, China.

\*\*Chercheur Boursier de M.A.S. of the Quebec Medical Research Council (F.R.S.Q.), and to whom request for reprints should be addressed.

**Abbreviations:** HCC, hepatocellular carcinoma; HHN, hepatic hyperplastic nodules; AAF, acetylaminofluorene; DEN, diethylnitrosamine.

††The term 'resistant hepatocyte' derives from observations that cells present in hyperplastic nodules are more resistant to various cytotoxic insults than are normal hepatocytes [3].

were carried out for the first time in experimental HHNs and hepatoma tissue.

## MATERIALS AND METHODS

### *Hepatic hyperplastic nodules induced by the 'resistant hepatocyte model' [3]*

Male Fischer rats weighing 125 g (~3 months of age) were administered diethylnitrosamine (DEN) in a 100-mg/kg dose orally, followed by AAF (0.02%) and partial hepatectomy. The presence of grossly visible hyperplastic nodules was confirmed in all livers by laparotomy soon after 'release'.

### *Long-term treatment with estrogen and/or tamoxifen*

Six weeks\* after release from AAF, rats were randomized into the following groups: (i) controls (i.e. no additional treatment); (ii) estrogen treatment (4.8, 12.0 and 24.0 µg/day delivered by subcutaneously implanted silastic implants containing estradiol-17β; Sigma Chemical Co., St. Louis, MO). The rate of release of estradiol-17β from silastic implants has been documented to be 2.4 µg/cm/day [6]; (iii) tamoxifen treatment (0.25, 1.0 and 2.5 mg in peanut oil s.c. biweekly; generously provided by ICI Pharmaceuticals, Wilmington, DE); (iv) combined treatment with estrogen and tamoxifen: animals receiving 4.8 µg/day of estradiol-17β also received biweekly injections of either 0.25, 1.0 or 2.5 mg tamoxifen. The number of animals initially present in each of these groups are depicted in Fig. 2 and the numbers remaining at the time of termination 10 months later are shown in Fig. 3. Animals were housed in pairs in wire bottom cages and were fed water and purina rat chow *ad lib*.

### *Collection of blood and tissues*

Following 10 months of treatment, animals were anesthetized using CO<sub>2</sub>:O<sub>2</sub> mixture (1:1) and blood was collected by aortic puncture. The liver was excised, rapidly weighed and samples were taken for histological sections. HHNs after separation from normal liver by careful dissection, were pooled for preparation of cytosol for receptor measurement. Estradiol containing silastic implants were removed and weighed at the time of sacrifice.

### *Cytoplasmic glucocorticoid, estrogen and progestin binding assay*

[6,7-<sup>3</sup>H]Dexamethasone (50–60 Ci/mmol) was used for the measurement of cytoplasmic

glucocorticoid receptor concentration. The apparent dissociation constant and the binding capacity of the cytosol receptor protein was determined as described by Giannopoulos [7]. The tissue was homogenized in 4 vol of buffer to be defined below and the homogenate was centrifuged at 105,000 g for 45 min. Samples of cytosol were incubated with increasing concentrations of the labeled hormone in the presence or absence of a 100-fold excess of unlabeled steroid for 3 hr at 4°C. The bound hormone was separated by dextran-coated charcoal and the data were analyzed by the method of Scatchard [8]. The relative affinities of various steroids were determined by incubating samples of cytosol with 25 nM labeled steroid in the presence of a 10- or a 100-fold excess of various unlabeled steroids. The cytoplasmic steroid receptor complex was characterized by sucrose density gradient centrifugation [9].

In these studies estrogen binding to cytosol was determined using a synthetic estrogen, [6,7-<sup>3</sup>H]ethinyl estradiol (40–45 Ci/mmol, New England Nuclear Corp., Boston, MA) instead of estradiol-17β, which is readily metabolized by liver cytosol as this metabolic activity interferes with the measurement of estrogen receptors in the liver [10]. Ethinyl estradiol has the added advantage of not binding either to serum estrogen-binding proteins [11] or to the high-capacity low-affinity estrogen binder present in adult male rat liver [12].

The dissociation constant and binding capacity of progesterone receptors was determined using a synthetic progestin, promegestone (R-5020), because it does not bind to corticosteroid-binding globulin or other plasma proteins [13]. For both estrogen and progestin receptor assays, tissue was homogenized in 4 vol of 5 mM phosphate, 1 mM monothiolglycerol buffer, pH 7.4, then centrifuged at 105,000 g for 45 min. Aliquots of the supernatant were incubated for 3 hr at 4°C with increasing concentrations of either labeled ethinyl estradiol or labeled promegestone in the presence or absence of 200-fold excess of the unlabeled steroid. A 5000-fold excess of cortisol was added to all tubes used for progestin receptor assay to prevent binding of labeled promegestone to glucocorticoid receptor proteins present in the cytosol [14].

### *Histology*

Sections (1–2 mm thick) were cut through each of the three major lobes of the liver and were fixed in 4% formalin. Hyperplastic nodules in H&E-stained sections were graded on a scale of 1–4 according to the subjective assessment of the proportion of liver tissue which they occupied as

\*This time interval was chosen such that we would be dealing with a greater proportion of persistent nodules in view of the fact that many HHN's, grossly visible after release, will disappear by the process of remodeling [3].

follows: 1+ = 0-24% involvement; 2+ = 25-49%; 3+ = 50-74%; and 4+ = 75-100%. The diagnosis of hepatocellular carcinoma (HCC) was made on accepted histological criteria [15] (see Fig. 5c), namely that the hepatocytes were arranged in trabecular pattern rather than single-cell plates and showed considerable variation in size, shape and staining characteristics. The nuclei also showed considerable variation and anisocytosis. Coded histological sections were examined independently and blindly by two pathologists (E.F. and R.H.).

#### Other determinations and statistics

Cytosol protein was measured by the method of Lowry *et al.* [16]. Differences between means were tested by the Student's *t* test and a probability of less than 0.05 was considered to be significant.

## RESULTS

#### Characterization of cytoplasmic estrogen progesterone and glucocorticoid receptors

Isolated hepatic hyperplastic nodules possessed cytoplasmic estrogen and glucocorticoid receptors in concentrations significantly reduced relative to adjacent normal liver (Fig. 1). In all cases the

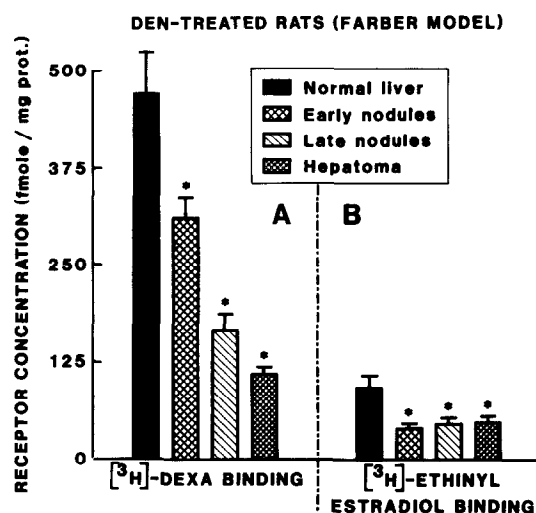


Fig. 1. Comparison of the glucocorticoid (panel A) and estrogen (panel B) receptor concentration in the cytosols from normal liver tissues ( $n = 12$ ), early ( $< 6$  months after release from AAF) ( $n = 7$ ) and late ( $> 6$  months after release from AAF and without histological evidence of malignant transformation;  $n = 6$ ) from carcinogen-treated rats according to the method of Solt *et al.* [3]. All values shown represent the mean  $\pm$  S.E.M. \* indicates a significant difference ( $P < 0.05$ ) between normal liver and hepatic hyperplastic nodules.  $n =$  No. of assays performed on tissue harvested and pooled from single livers.

dissociation constants of the receptors in HHNs were not significantly different from those of normal liver tissue. Assays for the presence of progesterone receptors did not demonstrate the presence of specific receptors in liver or HHNs.

The mean capacity of estrogen receptors in normal liver 342 days after release from AAF was 28.4 fmol/mg cytoplasmic protein ( $n = 8$ , range 0-119), representing a decreased concentration of 88.4% compared to liver not exposed to carcinogens. The capacity of estrogen receptors in livers harvested from animals treated (10 months) with tamoxifen alone ( $n = 7$ ) and tamoxifen and estradiol-17 $\beta$  ( $n = 8$ ) was reduced by 98.6 and 96.7% respectively relative to normal liver. No estrogen receptors were detectable in HHNs ( $n = 10$ ) and hepatomas ( $n = 5$ ) harvested from these groups. The capacity of estrogen receptors in the liver and tumor harvested from the single surviving estradiol-treated rat was 37.0 and 0.0 fmol/mg cytoplasmic protein respectively. It is likely that the absence of, or low cytoplasmic binding of, estrogen in the tissue of animals treated with tamoxifen and/or estradiol-17 $\beta$  was due to the occupation of receptor sites by exogenous ligands. Assays for cytoplasmic progesterone receptors in all the above-mentioned samples did not detect specific binding in any samples.

The long-term experiment was designed to document histological changes resulting from 10 months (300 days) of hormonal manipulation initiated 6 weeks after the induction of HHNs. These results were complicated by the very high mortality of animals treated with estradiol-17 $\beta$  alone; mean survival ( $\pm$ S.E.M.) for groups treated with 4.8, 12.0 and 24.0  $\mu$ g/day were  $184.4 \pm 22.6$ ,  $182.6 \pm 8.5$  and  $116.0 \pm 9.9$  days respectively (Fig. 2). Animals treated with tamoxifen alone or in combination with estradiol-17 $\beta$  did not die earlier than controls. Body weights of estrogen-treated rats were significantly less than those of controls and rats receiving tamoxifen alone or in combination with estradiol-17 $\beta$ . These weight differences were similar to those previously noted in animals bearing AAF-induced HHNs [5]. The grade of hyperplastic nodules (Figs 3 and 4) was significantly reduced in each group receiving tamoxifen alone and in those groups receiving estradiol-17 $\beta$  (4.8  $\mu$ g/day) in combination with tamoxifen (1.0 or 2.5 mg biweekly). The incidence of malignancy (Fig. 5) was significantly reduced in animals receiving tamoxifen 0.25 mg biweekly alone or in doses of 0.25, 1.0 and 2.5 mg biweekly in combination with 4.8  $\mu$ g/day of estradiol-17 $\beta$ . In rats treated with combined therapy there appeared to be a progressive decrease in nodule grade (Fig. 3) and incidence of malignant

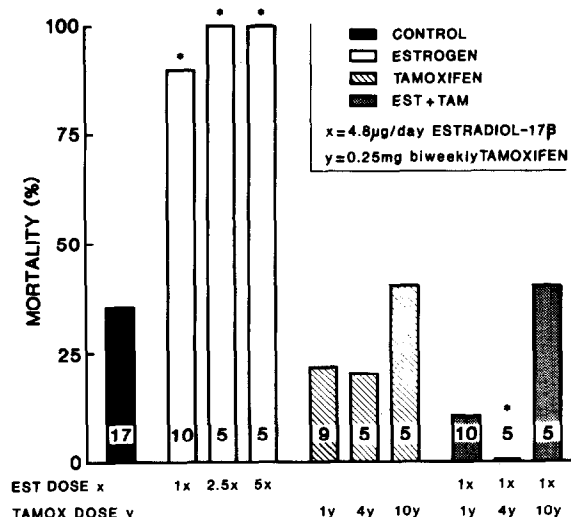


Fig. 2. Mortality observed in various groups of rats bearing 'resistant hepatocyte' hepatic hyperplastic nodules [3] prior to termination (342 days after release from tumor induction). The control group contained rats with HHNs who did not receive additional treatment. The other groups received treatment with estrogen (estradiol-17 $\beta$  silastic pellets implanted s.c.) and/or tamoxifen (s.c. injection biweekly) for 10 months (300 days). Mean survival  $\pm$  S.E.M. for groups treated with 4.8, 12.0 and 24.0  $\mu$ g/day estradiol-17 $\beta$  were  $184.4 \pm 22.6$ ,  $182.6 \pm 8.5$  and  $116.0 \pm 9.9$  days respectively. The numbers shown in each bar represent the number of animals in each group when hormonal treatment was initiated. \* indicates a significant difference ( $P < 0.05$ ) from the value for animals in the control group.

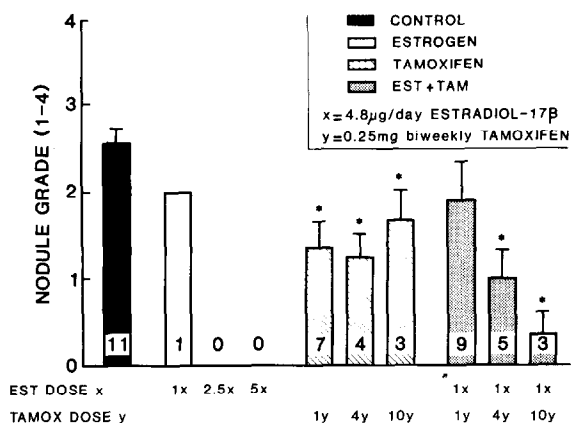


Fig. 3. The effect of 10 months of treatment with estradiol-17 $\beta$  and/or tamoxifen on the extent of liver replaced by hyperplastic nodules (grade). The proportion of a liver slice involved by hyperplastic nodules was graded on a scale of 1-4 as follows: 1+ = 0-24%; 2+ = 25-49%; 3+ = 50-74%; 4+ = 75-100% involvement. \* indicates a significant difference ( $P < 0.05$ ) from the value for the control group.

transformation of HHNs (Fig. 5) with increasing dosages of tamoxifen. Overall, if we examine the actual values as well as the significant statistical differences shown in Figs 2, 3 and 5, it is clear that combined treatment with tamoxifen and estradiol-17 $\beta$  was superior to tamoxifen alone, especially

with regard to mortality and incidence of malignancy. No data are available on the effects of different doses of estradiol-17 $\beta$  on nodule grade or malignant transformation in view of the high mortality in these groups. Autopsies of these animals ruled out malignant hepatoma, sepsis or other specific pathology as the cause of death (brain and pituitary were not examined). Clearly, combination therapy with single-dose estradiol-17 $\beta$  (4.8  $\mu$ g/day) and various doses of tamoxifen (0.25-2.5 mg) yielded optimal results with regard to reduction of mortality and of nodule grade, as well as the incidence of malignant transformation (Figs 2, 3 and 5).

## DISCUSSION

The key observation of this study is that long-term treatment with various doses of tamoxifen (0.25-2.5 mg biweekly) alone or in combination with a constant dose of estradiol-17 $\beta$  (4.8  $\mu$ g/day) inhibited the proliferation and malignant transformation of HHNs of the 'resistant hepatocyte model' [3]. These results confirm and extend results obtained with AAF-induced HHNs [5]. Thus far we have identified cytoplasmic estrogen receptors in early HHNs harvested from three experimental models [4]. In each case the concentration of estrogen receptors in tumor tissue was less than that of normal liver. In this experiment cytoplasmic estrogen receptors were assayed for the first time 10 months after randomization into treatment on control groups and were found to be either absent or present in very low concentration in HHNs and hepatoma tissue relative to normal liver. The apparent absence of measurable sex steroid receptors in liver and tumor tissue harvested from animals who had been treated with long-term estradiol-17 $\beta$  and/or tamoxifen was probably due to competitive binding by these exogenous compounds rather than to the absence of receptors. We were unable to document the presence of specific cytoplasmic receptors for progestin in all tissues assayed. Friedman *et al.* [17] reported similar results in malignant hepatic tumors harvested from humans, while MacDonald *et al.* claim to have documented progestin receptors in tissue harvested from a patient bearing a benign hepatic tumor [18]. It should be noted that while cytoplasmic estrogen receptors have been measured in rat liver and malignant hepatoma [9, 19], we are not aware of any published data for progestin receptors. The possibility that the concentrations of endogenous estrogens and progestins were elevated abnormally in animals not receiving exogenous steroids was not investigated. Nuclear receptors for sex steroids as

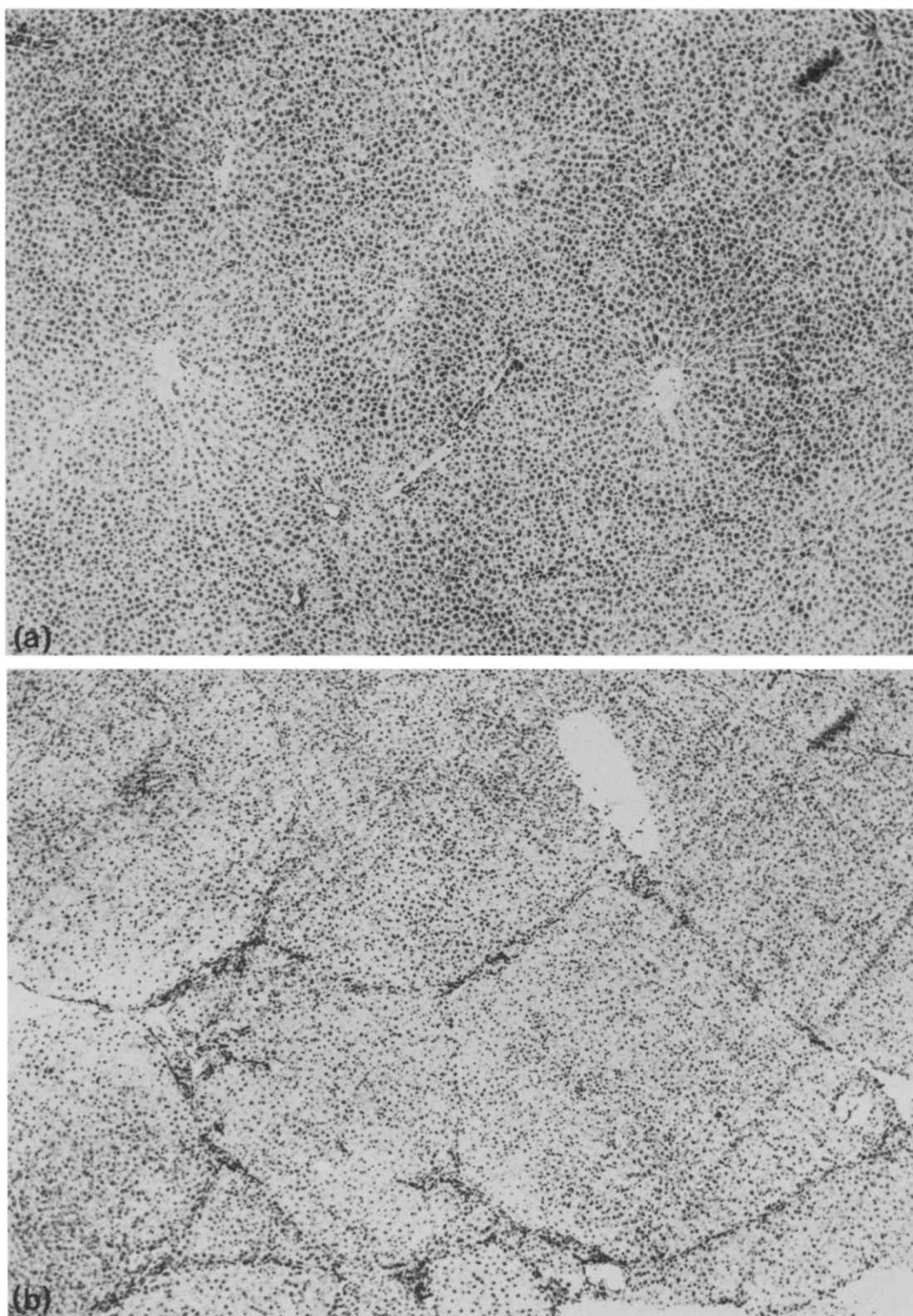
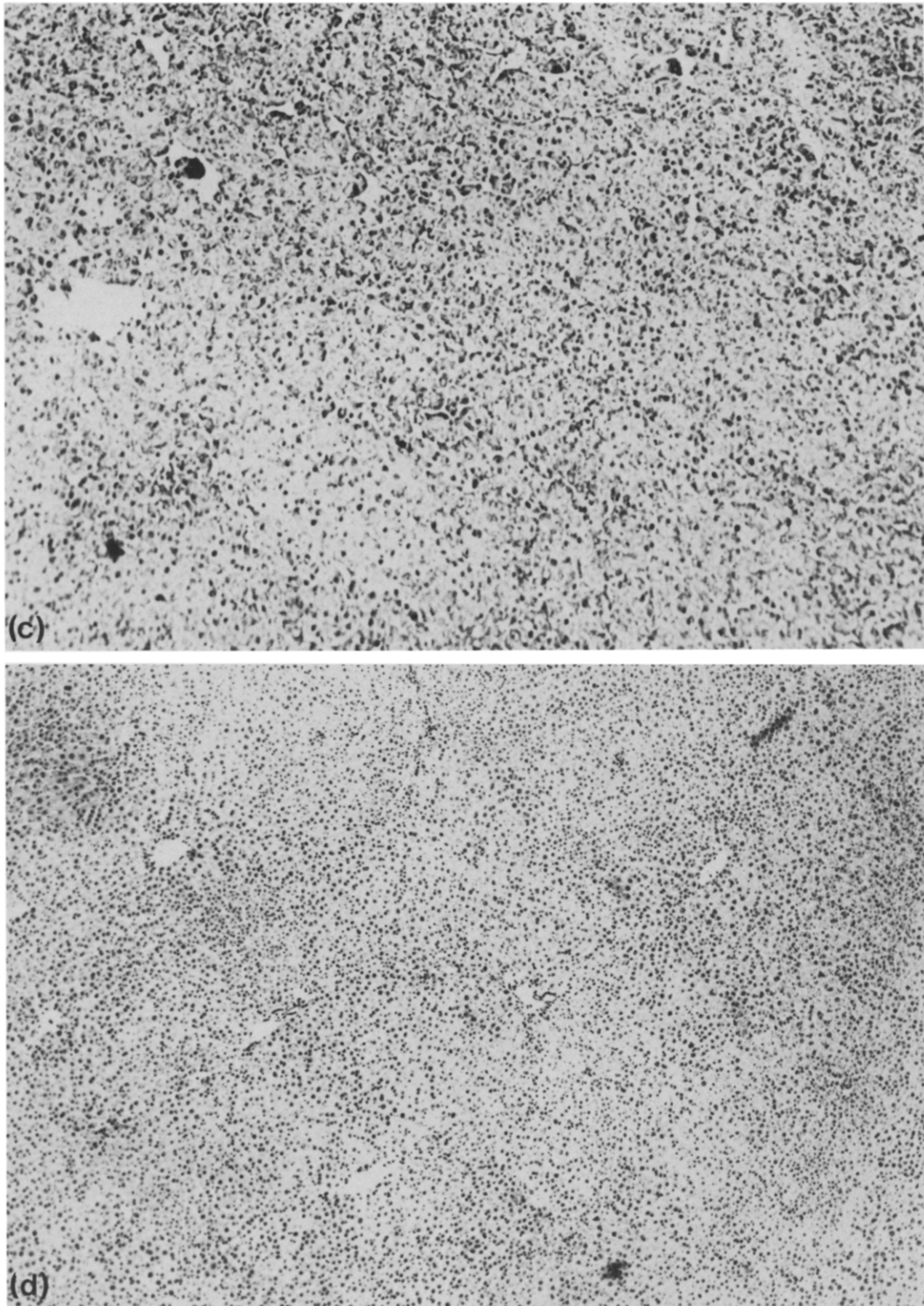


Fig. 4. Hematoxylin and eosin (H&E) stained sections obtained 342 days after induction of hepatic hyperplastic nodules according to the method of Solt et al. [3]. (a) Normal liver,  $\times 40$ ; (b) hepatic hyperplastic nodules; (c) focus of hepatocellular carcinoma in another area of tissue shown in Fig. 1b,  $\times 100$  (criteria for malignant transformation as described in Materials and Methods); (d) normalization of histological features following 10 months (300 days) of treatment with estradiol- $17\beta$  ( $4.8 \mu\text{g}$  daily) and tamoxifen ( $1.0 \text{ mg}$  biweekly) after release from AAF,  $\times 40$ .



*Fig. 4 (c and d).*



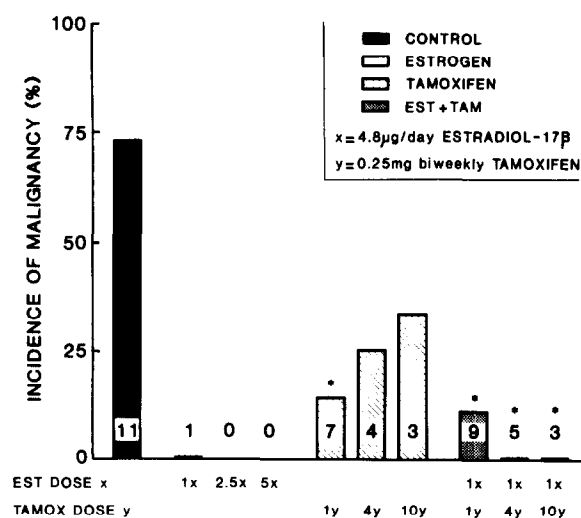


Fig. 5. The effect of treatment with estradiol-17 $\beta$  and/or tamoxifen on the incidence of malignant hepatoma. The criteria for malignancy are described in Materials and Methods. \* indicates a significant difference ( $P < 0.05$ ) from the value obtained for the control group.

well as specific anti-estrogen binding sites were not assayed in these experiments.

The pharmacologic dosages of estrogen and tamoxifen used in the long-term experiment were chosen empirically. Analysis of liver histology indicated that treatment with tamoxifen at three dose levels administered alone or in combination with a fixed dose of estradiol-17 $\beta$  reduced nodule grade and the incidence of malignant transformation (Figs 3 and 4). Similar results were obtained using AAF-induced HHNs, as described elsewhere [5]. The major difference between the results obtained with these two experimental models for HHNs was the very high mortality observed in the estrogen-treated rats bearing 'resistant hepatocyte model' HHNs [3]. As male Fischer 344 rats were used in both models, the high mortality may be due to the different methods used to induce HHNs. The 75% partial hepatectomy used in the 'resistant hepatocyte model' may lead to a relative paucity of normal hepatic parenchyma to "detoxify" estrogen. Taper observed excessive mortality after long-term treatment (300 days) of tumor-bearing rats with estradiol-17-phenylpropionate and estradiol benzoate, and attributed this to the frequent occurrence of hypophyseal hemorrhages [20]. While a dose-related reduction in food consumption, body weight gain and increased mortality have been well-documented

following the chronic administration of estrogen to rats [21], the mechanisms of these effects are poorly understood. It has been postulated that estradiol itself possesses 'anorectic activity' [22].

The ability of estrogen and tamoxifen to reverse the growth and malignant transformation of carcinogen-induced hyperplastic nodules may be mediated by specific intracellular receptors, as it is generally accepted that in the absence of hormone receptors it is unlikely that a given hormone or its antagonist will affect a target tissue [23]. Tamoxifen, a non-steroidal estrogen antagonist which binds to the estrogen receptor and translocates to the nucleus [24], can display a spectrum of activity, varying from pure antagonist through partial antagonist to full agonist, depending upon the animal species, target tissue and particular response parameter monitored. In the rat tamoxifen causes regression of hormone-dependent mammary tumors [25] and is a partial antagonist of estradiol-stimulated uterine growth [26]. In rat liver, however, tamoxifen appears to be a potent estrogen agonist as monitored by elevations of plasma renin substrate levels [27]. In addition, tamoxifen administered to rats significantly decreased the activity of hepatic microsomal aryl hydrocarbon hydroxylase and other mixed function oxidases [28]. Similar effects in rat liver have been documented after estrogen administration [29]. It is possible, therefore, that estradiol-17 $\beta$  and tamoxifen in our experiment were acting as 'estrogen agonists'. Clearly tamoxifen did not possess the 'toxic' effects of the pharmacological doses of estradiol-17 $\beta$ . In fact, the high mortality observed in estrogen-treated rats was prevented by simultaneous administration of tamoxifen. These observations remain unexplained.

Our results suggest that the mechanisms which control the growth and malignant transformation of HHNs may be influenced by the hormonal milieu. Identification of specific hormonally controlled steps in this process may have significant implications in preventing the malignant transformation of hepatic and other tumor types.

**Acknowledgements**—The authors wish to acknowledge the technical assistance of MM G. Lee and J. M. Legault. The continued interest and encouragement of Drs J. Adler and S. Solomon is gratefully acknowledged. We thank Ms B. Stewart for typing this manuscript.

## REFERENCES

1. Popper H, Selikoff IJ, Maltoni C, Squire RA, Thomas LB. Comparison of neoplastic lesions in man and experimental animals. In: Hiat HH, Watson JD, Winsten JA, eds. *Origins of Human Cancer*. New York, Cold Spring Harbor Laboratory, 1977, 135a.

2. Epstein S, Ito N, Merkow L, Farber E. Cellular analysis of liver carcinogenesis: the induction of large hyperplastic nodules in the liver with 2-fluorenylacetamide or ethionine and some aspects of their morphology and glycogen metabolism. *Cancer Res* 1967, **27**, 1702-1711.
3. Solt D, Medline A, Farber E. Rapid emergence of carcinogen-induced hyperplastic lesions in a new model for the sequential analysis of liver carcinogenesis. *Am J Pathol* 1977, **88**, 595-618.
4. Mulay S, Farber E, Adler J, Mishkin S. Demonstration of cytoplasmic estrogen receptors in premalignant hepatic tumors; comparison with the concentration of corticosteroid receptors. *Clin Invest Med* 1981, **4**, 14B.
5. Mishkin SY, Farber E, Ho RK, Mulay S, Mishkin S. Evidence for the hormone dependency of hepatic hyperplastic nodules; inhibition of malignant transformation after exogenous  $17\beta$  estradiol and tamoxifen. *Hepatology* 1983, **3**, 308-316.
6. Robaire B, Ewing LL, Irby DC, Desjardins C. Interactions of testosterone and estradiol- $17\beta$  on the reproductive tract of the male rat. *Reproduction* 1979, **21**, 455-463.
7. Giannopoulos G. Variations in the level of cytoplasmic glucocorticoid receptor in lungs of various species at different developmental stages. *Endocrinology* 1974, **94**, 450-458.
8. Scatchard G. The attraction of proteins for small molecules and ions. *Ann NY Acad Sci* 1949, **51**, 661-672.
9. Chamness GC, Costlow ME, McGuire WL. Estrogen receptor in the rat liver and its dependence on prolactin. *Steroids* 1975, **26**, 363-371.
10. Eisenfeld HA, Aten RF, Haselbacher GK, Halpern K. Specific macromolecular binding of estradiol in mammalian liver supernatant. *Biochem Pharmacol* 1977, **26**, 919-922.
11. Raynaud JP, Mercier-Bodarel C, Beaulieu EE. Rat estradiol binding plasma protein (EBP). *Steroids* 1971, **18**, 767-788.
12. Dickson RB, Aten RF, Eisenfeld A. An unusual sex binding protein in mature male rat liver cytosol. *Endocrinology* 1978, **103**, 1636-1646.
13. McGuire WL, Horowitz KB, Pearson DH, Segaloff A. Current status of estrogen and progesterone receptors in breast cancer. *Cancer* 1977, **39**, 2934-2947.
14. Lippman M, Huff K, Bolman G, Neifeld JP. Interaction of R-5020 with progesterone and glucocorticoid receptors in human breast cancer and peripheral blood lymphocytes *in vitro*. In: McGuire WL, Raymond JP, Beaulieu EE, eds. *Progress in Cancer Research and Therapy*. New York, Raven Press, 1977, Vol. 4, 193-210.
15. Farber E, Cameron R. The sequential analysis of cancer development. *Adv Cancer Res* 1980, **31**, 125-226.
16. Lowry OH, Rosebrough NJ, Farr AL, Randall RJ. Protein measurement with the Folin phenol reagent. *J Biol Chem* 1951, **193**, 265-275.
17. Friedman MA, Demanes DF, Hoffman PG. Hepatomas: hormone receptors and therapy. *Am J Med* 1982, **73**, 362-366.
18. MacDonald JS, Lippman ME, Wooley PV, Petrucci PP, Schein PS. Hepatic estrogen and progesterone receptors in an estrogen-associated hepatic neoplasm. *Cancer Chemother Pharmacol* 1978, **1**, 135-138.
19. Molteni A, Bahu RM, Battifora HA *et al.* Estradiol receptor assays in normal and neoplastic tissues, a possible aid for tumor differentiation. *Ann Clin Lab Sci* 1979, **9**, 103-108.
20. Taper HS. The effect of estradiol-17-phenylpropionate and estradiol benzoate on *N*-nitrosomorpholine-induced liver carcinogenesis in ovariectomized female rats. *Cancer* 1978, **42**, 462-467.
21. Gibson JP, Newberne JW, Kuhn WL, Elsea JR. Comparative chronic toxicity of three oral estrogens in rats. *Toxicol Appl Pharmacol* 1967, **11**, 489-510.
22. Mordes JP, Longcope C, Rossini AA. The anorectic activity of the LTW(M) tumor may be due to estrogen. Sixty-fourth Annual Meeting of the Endocrine Society, June 1982, San Francisco, CA, 443.
23. McGuire WL. Current status of estrogen receptors in human breast cancer. *Cancer* 1975, **36**, 638-644.
24. Jordan VC, Dix CJ, Rowsby L, Prestwich G. Studies on the mechanism of action of the nonsteroidal antiestrogen tamoxifen (I.C.I. 46,474) in the rat. *Mol Cell Endocrinol* 1977, **7**, 177-192.
25. Katzenellenbogen BS, Bhakoo HS, Ferguson ER. Tissues and tumors. *Recent Prog Horm Res* 1979, **35**, 259-300.
26. Jordan VC, Allen KE, Dix CJ. Pharmacology of tamoxifen in laboratory animals. *Cancer Treat Rep* 1980, **64**, 745-759.



27. Kneiffel MA, Katzenellenbogen BS. Comparative effects of estrogen and antiestrogen on plasma renin substrate levels and hepatic estrogen receptors in the rat. *Endocrinology* 1981, **108**, 545-552.
28. Al-Turk WA, Stohs SJ, Roche EB. Effects of tamoxifen treatment on liver, lung and intestinal mixed function oxidases in male and female rats. *Drug Metab Disp* 1981, **9**, 327-330.
29. Williams MT. Effects of estradiol on enzymes associated with benzo(A)pyrene metabolism. *Fed Proc* 1982, **41**, 1428.